

MANAGEMENT OF DEFORMATIONAL PLAGIOCEPHALY: REPOSITIONING VERSUS ORTHOTIC THERAPY

JOHN M. GRAHAM, JR, MD, SCD, MAYELA GOMEZ, BS, ANDY HALBERG, BS, DAWN L. EARL, CPNP, MSN,
JEANNIE T. KREUTZMAN, CPNP, MSN, JINRUI CUI, MS, AND XIUQING GUO, PHD

Objectives We compare positioning with orthotic therapy in 298 consecutive infants referred for correction of head asymmetry.

Study design We evaluated 176 infants treated with repositioning, 159 treated with helmets, and 37 treated with initial repositioning followed by helmet therapy when treatment failed. We compared reductions in diagonal difference (RDD) between repositioning and cranial orthotic therapy. Helmets were routinely used for infants older than 6 months with DD >1 cm.

Results For infants treated with repositioning at a mean age of 4.8 months, the mean RDD was 0.55 cm (from an initial mean DD of 1.05 cm). For infants treated with cranial orthotics at a mean age of 6.6 months, the mean RDD was 0.71 cm (from an initial mean DD of 1.13 cm).

Conclusions Infants treated with orthotics were older and required a longer length of treatment (4.2 vs 3.5 months). Infants treated with orthosis had a mean final DD closer to the DD in unaffected infants (0.3 ± 0.1 cm), orthotic therapy was more effective than repositioning (61% decrease versus 52% decrease in DD), and early orthosis was significantly more effective than later orthosis (65% decrease versus 51% decrease in DD). (*J Pediatr* 2005;146:258-62)

Between 1981 and 1991, epidemiologic studies showed a strong association between infants sleeping on their stomachs and death from sudden infant death syndrome (SIDS). In 1992, infants who slept in prone position had as much as an 11.7 times higher risk for SIDS, and it was recommended that infants be positioned on their backs for sleep, except in cases of prematurity, gastroesophageal reflux, or obstructive sleep apnea.¹ This decreased the prevalence of prone infant sleeping from 70% in 1992 to 10.5% in 1997 and decreased the incidence of SIDS from 2.6 per 1000 in 1986 to 1.0 per 1000 in 1998.²

In 1974, plagiocephaly occurred once in every 300 live births among prone-sleeping infants.³ After the "Back to Sleep" campaign was initiated, the frequency of plagiocephaly increased to 1 in 60 in 1996.⁴⁻⁶ Among 7609 Dutch infants screened for positional plagiocephaly before the age of 6 months, the incidence of plagiocephaly was 8.2%, with brachycephaly noted in 10%. Deformity persisted in nearly one third when reexamined at age 2 to 3 years.⁷

Among 1086 Hong Kong infants with congenital torticollis, 91% of infants improved when treated with manual stretching, and craniofacial asymmetry also resolved.⁸ Plagiocephaly has been treated with either early physical therapy and repositioning⁹ or helmet therapy,¹⁰⁻¹³ but no studies compared outcomes from both approaches with large enough numbers to provide evidence-based guidelines for treatment. Most authors agree that if there is little improvement in head shape in young infants being treated with repositioning and physical therapy, orthotic therapy should be initiated while there is still enough residual head growth to allow for correction.¹¹ We compared repositioning with helmet therapy, demonstrating that both techniques work when used appropriately with neck physical therapy.

See related article,
p 253.

From the Medical Genetics Institute, Ahmanson Department of Pediatrics, Steven Spielberg Pediatric Research Center, Burns and Allen Research Institute, Cedars-Sinai Medical Center and Department of Pediatrics, University of California, Los Angeles, California.

Supported by SHARE's Childhood Disability Center, the Steven Spielberg Pediatric Research Center, the Cedars-Sinai Burns and Allen Research Institute, the Skeletal Dysplasias NIH/NICHD Program Project Grant (HD22657-11), and the Medical Genetics NIH/NIGMS Training Program Grant (GM08243).

Submitted for publication Feb 3, 2004; revision received Aug 24, 2004; accepted Oct 1, 2004.

Reprint requests: Dr John M. Graham, Jr, Clinical Genetics and Dysmorphology, Cedars-Sinai Medical Center, 444 South San Vicente Blvd, #1001, Los Angeles, CA 90048.

0022-3476/\$ - see front matter

Copyright © 2005 Elsevier Inc. All rights reserved.

10.1016/j.jpeds.2004.10.016

DD	Diagonal differences	SIDS	Sudden infant death syndrome
RDD	Reductions in diagonal difference		

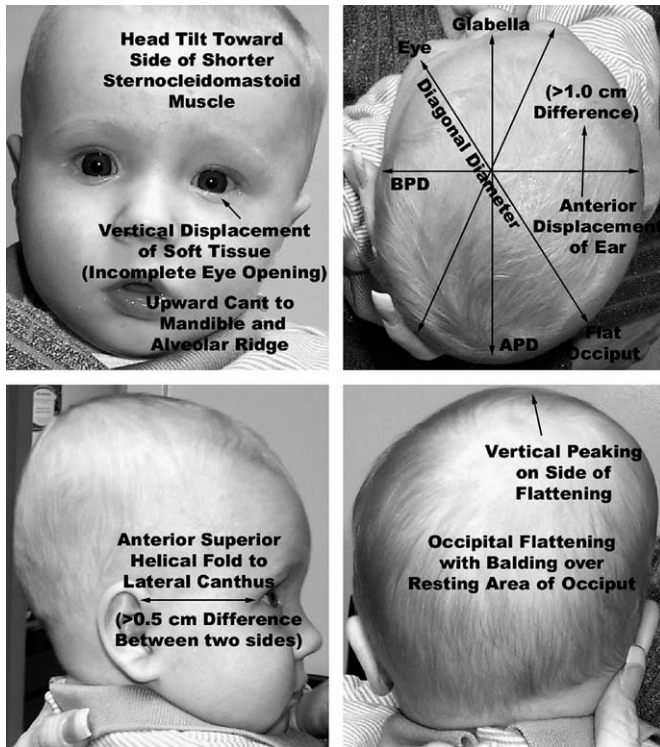


Figure 1. This infant shows all key features of torticollis-plagiocephaly deformation sequence, with cranial measurements depicted on top of his skull, before initiation of helmet therapy at age 5 months.

METHODS

Longitudinal data were collected on 298 consecutive normal infants, who were referred and treated for plagiocephaly at Cedars-Sinai Medical Center between January 1, 1994, and December 31, 2001. Cranial diagonal differences (DD) were compared before and after treatment. Institutional Review Board review was obtained to use anonymized patient care data. We compared size at birth and at the last treatment visit between the two sexes. Cranial diagonal measurements were taken by anthropometric metal cranial calipers (B. Braun Medical Products, Aesculap Division, Tuttingen, Germany), as shown in the diagram in Figure 1. Each measurement was taken 3 times and averaged by one of two pediatric nurse practitioners. There were not significant differences in measurement between practitioners when measuring the same patients. The normal DD in 36 healthy infants measured between 4 and 12 months (average age, 6.8 months) was 0.3 ± 0.1 cm, and this was considered to be our target DD. Since this was a clinical study of outcomes in infants referred for plagiocephaly, we routinely recommended helmets for all infants older than 6 months with a DD greater than 1 cm, since this was the previous standard of care.^{12,13} For infants referred at 4 months or younger, we began treatment with repositioning. For patients between 4 and 6 months of age, both treatment options were offered, and parents chose one option and were followed at monthly intervals to monitor progress and encourage compliance. Neonates who were

Table I. Treatment group characteristics (mean \pm SD) by sex

	Boys	Girls
Birth weight (g)	3272 \pm 694	3289 \pm 724
Birth length (cm)	48 \pm 4.5	48.5 \pm 4.8
Weight at last visit (g)	9130 \pm 1681	8516 \pm 1990
Length at last visit (cm)	70.3 \pm 6.6	69.1 \pm 8.8
Age at last visit (mo)	8.2 \pm 3.2	9.0 \pm 4.8

referred for torticollis were treated with physical therapy and did not develop plagiocephaly, and they were not included in this study. Most infants referred for plagiocephaly were too old to detect sternomastoid tumors, and the presence or absence of such tumors was not routinely documented. All infants with plagiocephaly had some associated torticollis, and they were treated with physical therapy and followed at monthly intervals. Patients treated initially with physical therapy and repositioning, who failed to reduce their DD to less than 1.0 cm by 7.4 months, were treated with helmets. Their data were included in each treatment group for the period of time spent in each treatment modality. Plastic cranial orthotic helmets were fitted by using methods previously described by Clarren.^{12,13} Statistical *t* tests, using the SAS software package, were used to compare the effect of repositioning versus helmet therapy.

RESULTS

The mean age of 298 infants treated for plagiocephaly was 5.4 months; the mean length of treatment was 4.3 months; 70% were boys; 68% were left-sided. Size differences between boys and girls were not significant (Table I). Among 176 infants treated with repositioning, the mean RDD was 0.55 cm (± 0.33), from a starting mean DD of 1.05 cm at 4.8 months. In 159 infants treated with helmets, the mean RDD was 0.71 cm (± 0.36), from a mean starting DD of 1.13 cm at 6.6 months. The final DD for repositioning was 0.50 cm (± 0.37), versus 0.42 cm (± 0.28) for orthotic therapy (Table II). Despite no significant difference in starting DD, the final mean DD in the helmeted group (0.42 cm) was not significantly different from the target DD (0.30 ± 0.1 cm). The mean final DD for the repositioned group (0.50 cm) was significantly more asymmetric. The mean percentage decrease for the orthotic group (61%) was significantly greater than the mean percentage decrease for the repositioning group (52%). Severe cases that presented early were treated with initial repositioning, followed by helmet therapy if they still had a 1.0 cm DD at an average age of 7.3 months. This group reached a mean final DD of 0.40 cm after a mean of 5.1 months (1.94 months for repositioning and 3.14 months for helmet). Among 37 infants who failed initial treatment with repositioning, their initial mean DD was 1.46 cm when treatment started at mean age 5.06 months, with a mean RDD of 0.56 by mean age 7.4 months, at

Table II. Mean values (SD) by treatment group

	Repositioning	Helmet	P value
N	176	159	
Starting DD (cm)	1.05 (0.45)	1.13 (0.38)	.076
Starting age (mo)	4.8 (1.7)	6.6 (1.7)	<.0001
Final DD (cm)	0.5 (0.32)	0.42 (0.42)	.007
Final age (mo)	8.3 (3.7)	10.9 (2.7)	<.0001
RDD (cm)	0.55 (0.33)	0.71 (0.36)	<.0001
RDD/starting DD	0.52 (0.22)	0.61 (0.20)	<.0001
Length of therapy (mo)	3.5 (3.5)	4.2 (2.2)	.024

which time helmet therapy was begun for another 2.7 months before reaching the target DD of 0.40 cm. Their improvement with repositioning was no different from our repositioning group, and parents were compliant, but the initial degree of plagiocephaly in this group was too severe to correct with repositioning alone.

To evaluate the effect of age on helmet treatment, we compared outcomes in 44 children who started treatment at an age of 8 months or greater with outcomes in 115 infants who started treatment before this age (Table III). The mean starting age in these younger infants was 5.8 months, with an initial DD of 1.14 cm. After a mean RDD of 0.76 cm (± 0.36), the final mean DD was 0.37 cm (± 0.22) after a mean treatment time of 4.4 months. The mean age of helmet initiation in older infants was 8.6 months, with a mean starting DD of 1.10 cm and a mean final DD of 0.51 cm (± 0.28) after a mean of 3.73 months in treatment. In older infants, the mean final DD was larger, with a smaller RDD, and the percentage decrease in DD was significantly less (51% vs 65%).

DISCUSSION

Before 1992, anterior deformational plagiocephaly predominated when infants slept on their stomachs.¹⁴ Among supine-sleeping infants with torticollis, one side of their occiput (more commonly the right side) becomes flattened, resulting in posterior deformational plagiocephaly. The incidence of torticollis was 1.3% among 250,000 Hong Kong infants followed in a prospective study of 1086 patients with congenital muscular torticollis seen in one center over a 12-year period.⁸ Torticollis was more commonly left-sided, with a 3:2 incidence of affected boys versus girls,⁸ which is similar to the incidence of congenital right-sided occipital flattening and male predominance for cranial asymmetry noted in healthy newborn infants.¹⁶ The laterality of birth head position corresponds to the side of torticollis.¹⁷ Among the Hong Kong cases of torticollis, 90.1% had clinically obvious craniofacial asymmetry, and this craniofacial asymmetry resolved with torticollis treatment (Professor Jack Cheng, personal communication). Initiation of neck physical therapy before 3 months is usually effective in correcting torticollis in compliant families.¹⁵

Our study found no difference in size at birth or later in infancy between affected boys and girls (Table I), suggesting

Table III. Mean values (SD) for helmet therapy babies by age group

	Helmet before age 8 mo	Helmet at age 8 mo or older
n	115	44
Starting DD (cm)	1.14 (0.37)	1.10 (0.39)
Starting age (mo)	5.8 (1.1)	8.6 (1.3)
Final DD (cm)	0.38 (0.22)	0.51 (0.28)
Final age (mo)	10.3 (2.5)	12.4 (2.8)
RDD* (cm)	0.76 (0.36)	0.58 (0.33)
RDD/starting DD	0.65 (0.19)	0.51 (0.20)
Length of therapy (mo)	4.4 (2.4)	3.7 (1.7)

*Significant difference between two groups ($P = .004$ for RDD and $.0001$ for RDD/starting DD).

that sex differences in the occurrence of torticollis may relate to some other factor, such as hormonal differences. Testosterone may accentuate muscular action in male fetuses, and relaxing hormones may affect female connective tissues. Girls may be protected from torticollis for the same reasons that make them more susceptible to developmental dysplasia of the hip.

Torticollis is more frequent in multiple births and usually affects the bottom fetus in vertex presentation.¹⁸ Findings that help to differentiate deformational plagiocephaly from craniosynostosis include forward ear placement, prominent mandibular sulcus with mandibular tilt, uplifted lower helix and smaller ear on the side of the torticollis, and unilateral epicanthal fold in cases with deformational plagiocephaly. Early signs of torticollis include an eye on the side of the torticollis that appears less open due to vertical displacement of the soft tissues of the cheek from pressure on the mandible (Figure 1). There may also be difficulty nursing from both breasts due to inability to turn the neck equally to both sides.

Early supervised tummy-time promotes prone motor skill development as well as neck range of motion. Prone positioning corrects positional preference, since positional preference was documented in only 2.4% of prone-sleeping Swedish infants, versus 19% of children who slept in supine position.¹⁹ Before the "Back to Sleep" campaign, many infants self-treated their own postural torticollis by turning their heads from side to side while sleeping in the prone position, and encouragement of tummy time has the same effect.

In a prospective study of 114 infants treated with either head repositioning (63 infants) or helmet therapy (51 infants), cranial symmetry was significantly better in infants treated with helmets than in those treated with positioning.²⁰ Of 98 patients with positional head deformation, 3 had severe and progressive deformation requiring surgery, and the rest were successfully treated with changes in sleeping position or helmet therapy.²¹ Many infants with positional plagiocephaly will improve with repositioning and neck physical therapy, but severe cases may require helmet therapy to achieve adequate resolution.^{10,20-23}

Among our 298 patients, the average length of treatment with helmet orthosis was 4.2 months for infants who averaged 6.6 months of age at the initiation of treatment. Younger infants with mild-moderate plagiocephaly were successfully treated with repositioning and physical therapy (Figure 2), and earlier treatment was significantly more successful than later treatment. There is no evidence that treatment after age 12 months of age provides significant benefit.^{11,20-24} Orthotic treatment does not restrict cranial growth but rather redirects subsequent cranial growth into a symmetric shape.²⁴ Positional plagiocephaly can have permanent effects, as demonstrated by purposeful artificial cranial deformation in many primitive cultures during the first 6 to 8 months of life.²⁵ Clinical reports^{26,27} confirm that altered head shapes can persist throughout life, and failure to treat muscular torticollis results in persistent facial asymmetry, cervical scoliosis, and persistent deformational plagiocephaly.^{26,27}

Moss⁹ reported on 66 infants with mild to moderate plagiocephaly (defined as cranial vault asymmetry of 1.2 cm or less) who were treated with head repositioning and physical therapy. Cranial vault asymmetry was decreased by an average of 0.45 cm over an average of 4.5 months. These results are similar to those obtained by Ripley et al (1994),¹⁰ who reduced cranial asymmetry by an average of 0.49 cm in 46 infants treated with orthotic helmets for an average of 4.3 months. Pollack et al¹¹ (1997) studied 69 infants with plagiocephaly (35 infants treated with repositioning alone and 34 infants who failed repositioning and required orthotic therapy). Both groups ultimately achieved normal head shapes, except for 5 infants who were older than 12 months when treatment was initiated. They recommended that if little improvement results from 6 to 8 weeks of repositioning in young infants receiving physical therapy for congenital muscular torticollis, then cranial orthotic therapy should be considered while there is still enough residual rapid head growth to allow for timely correction.¹¹

We collected longitudinal data on 298 otherwise normal infants treated between 1994 and 2001. Cranial diagonal diameters were measured before and after treatment (Figure 1). All parents were instructed to provide neck physical therapy, and infants with a diagonal difference greater than 1.0 cm at 6 months of age were corrected with helmet orthoses. The effectiveness of treatment was measured by the reduction in diagonal difference (RDD). The normal diagonal difference in healthy infants measured between 4 and 12 months (average age, 6.8 months) is 0.3 ± 0.1 cm. Correction of the head shape, documented by a diagonal difference within this normal range, took an average of 4 to 5 months (longer in older or more severe cases).

For infants treated with repositioning, the mean RDD was 0.55 cm (from an initial mean DD of 1.05 cm), which is consistent with previous studies.²² For infants treated with cranial orthosis, the mean RDD was 0.71 (from an initial mean DD of 1.13 cm). Repositioning resulted in a 52% decrease in DD, whereas orthotic therapy resulted in a 61% decrease. Though these changes appear small in magnitude, they were statistically significant (Table II). Treatment with a helmet

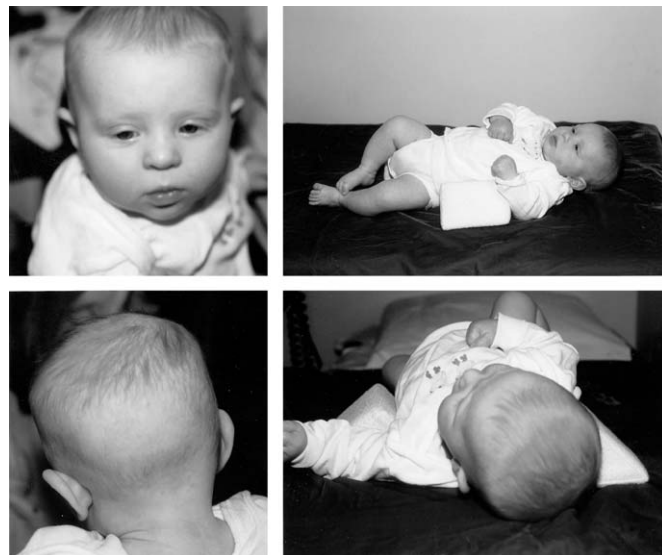

Figure 2. This girl with torticollis-plagiocephaly deformation sequence was treated entirely with neck physical therapy and repositioning, using an infant positioning device between ages 3 and 9 months. She is shown here part way through her therapy in a three-quarters turn, resting on her left occiput, with her bald spot shifted from the right previously flattened occiput to the right occiput.

after age 10 months was not adequately evaluated. One case treated at almost 10 months had a reduction in diagonal difference of 0.9 cm, with a final diagonal difference of 0.3 cm after 7 months in helmet therapy. Another case treated at 15 months for 9 months had a 0.5-cm reduction in diagonal difference, reducing his starting diagonal difference from 2.0 to 1.5 cm. Orthotic treatment after age 12 months shows little promise for significant correction, and significant asymmetry can persist, but with consistent reshaping techniques during early infancy, a more symmetric head shape can be achieved.

Positioning devices that allow the infant to be positioned in a three-quarters turn, with the head resting on the occipital prominence, can be effective. With consistent repositioning, the bald spot migrates from the previously flattened site toward the occipital prominence (Figure 2). It is important to warn the parents not to simply position the infant on the side of his/her head to prevent further occipital flattening. This does not correct cranial asymmetry and may be a dangerous sleeping position if the infant turns over and becomes prone. If initiated by 3 months, conservative treatment of torticollis with physical therapy is very effective, resulting in full passive range of motion and no facial asymmetry in more than 90% of compliant families.^{8,15} The more severe the neck restriction, the longer the required duration of physical therapy to achieve full range of motion.^{8,15}

Limitations to this study include lack of follow-up beyond the first year of life, lack of random assignment into treatment groups, and inability to quantify how the impact of small, statistically significant differences in outcome might relate to parental perceptions of cosmetic significance. Despite these limitations, we recommend that pediatricians attempt to identify infants with torticollis during early infancy and treat

this condition with physical therapy. In all infants, early encouragement of “tummy-time” can help resolve postural torticollis, and early management of head position during sleep can prevent the development of aberrant head shapes.²⁸ When physical therapy and repositioning fail to treat or prevent plagiocephaly and there is more than 1 cm difference between the two cranial diagonal differences at age 6 months, orthotic therapy is effective in correcting such asymmetry. Delays in initiating corrective treatment until later infancy may lead to incomplete or ineffective correction even if orthotic therapy is initiated, so early diagnosis and treatment is essential.

REFERENCES

1. AAP Task Force on Infant Positioning and SIDS: positioning and SIDS. *Pediatrics* 1992;89:1120-6.
2. Paris C, Remler R, Daling JR. Risk factors for sudden infant death syndrome: changes associated with sleep position recommendations. *J Pediatr* 2001;139:771-7.
3. Dunn PM. Congenital sternomastoid torticollis: an intrauterine postural deformity. *Arch Dis Child* 1974;49:824-5.
4. Argenta LC, David LR, Wilson JA, Bell WO. An increase in infant cranial deformity with supine sleeping position. *J Craniofac Surg* 1996;7:5-11.
5. Turk AE, McCarthy JG, Thorne CHM, Wisoff JH. The “Back to Sleep Campaign” and deformational plagiocephaly: is there cause for concern? *J Craniofac Surg* 1996;7:12-8.
6. Kane AA, Mitchell LE, Craven KP, Marsh JL. Observations on a recent increase in plagiocephaly without synostosis. *Pediatrics* 1996;97:877-85.
7. Boere-Boonekamp MMM, van der Linden-Kuiper LT. Positional preference: prevalence in infants and follow-up after two years. *Pediatrics* 2001;107:339-43.
8. Cheng JCY, Wong MWN, Tang SP, Chen TMK, Shum SLF, Wong EMC. Clinical determinants of the outcome of manual stretching in the treatment of congenital muscular torticollis in infants. *J Bone Joint Surg* 2001; 83-A:679-87.
9. Moss S. Nonsurgical, nonorthotic treatment of occipital plagiocephaly: what is the natural history of the misshapen neonatal head? *J Neurosurg* 1997; 87:667-70.
10. Ripley CE, Pomatto J, Beals SP, Joganic EF, Manwaring KH, Moss SD. Treatment of positional plagiocephaly with dynamic orthotic cranioplasty. *J Craniofac Surg* 1994;5:150-60.
11. Pollack I, Losken H, Fasick P. Diagnosis and management of posterior plagiocephaly. *Pediatrics* 1997;99:180-5.
12. Clarren SK. Helmet therapy for plagiocephaly and congenital muscular torticollis. *J Pediatr* 1979;94:43-6.
13. Clarren SK. Plagiocephaly and torticollis: etiology, natural history, and helmet therapy. *J Pediatr* 1981;98:92-5.
14. Bruneteau RJ, Mulliken JB. Frontal plagiocephaly: synostotic, compensational, or deformational. *Plast Reconstr Surg* 1992;89:21-31.
15. Emery C. The determinants of treatment duration for congenital muscular torticollis. *Phys Ther* 1994;74:921-9.
16. Peitsch WK, Keefer CH, LaBrie RA, Mulliken JB. Incidence of cranial asymmetry in healthy newborns. *Pediatrics* 2002;110:e72.
17. Golden KA, Beals SP, Littlefield TR, Pomatto JK. Sternocleidomastoid imbalance versus congenital muscular torticollis: their relationship to positional plagiocephaly. *Cleft Palate Craniofac J* 1999;36:256-61.
18. Littlefield TR, Kelly KM, Pomatto JK, Beals SP. Multiple-birth infants at higher risk for development of deformational plagiocephaly. *Pediatrics* 1999;103:565-9.
19. Palmén K. Prevention of congenital dislocation of the hip: the Swedish experience of neonatal treatment of hip joint instability. *Acta Orthop Scand* 1984;55:58-67.
20. Mulliken JB, van der Woude DL, Hansen M, LaBrie RA, Scott RM. Analysis of posterior plagiocephaly: deformational versus synostotic. *Plast Reconstr Surg* 1999;103:371-80.
21. Huang MHS, Gruss JS, Clarren SK, Mouradian WE, Cunningham ML, Roberts TS, et al. The differential diagnosis of posterior plagiocephaly: true lambdoid synostosis versus positional molding. *Plast Reconstr Surg* 1996; 98:765-76.
22. Littlefield TR, Beals SP, Manwaring KH, Pomatto JK, Joganic EF, Golden KA, et al. Treatment of craniofacial asymmetry with dynamic orthotic cranioplasty. *J Craniofac Surg* 1998;9:11-7.
23. Kelly KM, Littlefield TR, Pomatto JK, Ripley CE, Beals SP, Joganic EF. Importance of early recognition and treatment of deformational plagiocephaly with orthotic cranioplasty. *Cleft Palate Craniofac J* 1999;36: 127-30.
24. Kelly KM, Littlefield TF, Pomatto JK, Manwaring KH, Beals SP. Cranial growth unrestricted during treatment for deformational plagiocephaly. *Pediatr Neurosurg* 1999;30:193-9.
25. Dingwall EJ. *Artificial Cranial Deformations: A Contribution to the Study of Ethnic Mutilation*. London: John Bale, Sons, & Danielsson, Ltd; 1931.
26. Putnam GD, Postlethwaite KR, Chate RA, Ilankovan V. Facial scoliosis: a diagnostic dilemma. *Int J Oral Maxillofac Surg* 1993; 22:324-7.
27. Slate RK, Posnick JC, Armstrong DC, Buncic JR. Cervical spine subluxation associated with congenital muscular scoliosis and craniofacial asymmetry. *Plast Reconstr Surg* 1993;91:1187-95.
28. Persing J, James H, Swanson J, Kattwinkel J. Prevention and management of positional skull deformities in infants. *Pediatrics* 2003;112: 199-202. Letters to the Editor; *Pediatrics* 2003;113:422-4.